



ICCS

19<sup>th</sup> International Conference on Wound Management  
London (UK) - 25-26 May 2017



## **SiO<sub>2</sub>-Ag<sup>+</sup>Chlorex vs SilverSulfaDiazine: an "in vitro" and "in vivo" silver challenge**

R. Cassino, V. Dissette, C.A. Bignozzi, D. Pazzi

### **BACKGROUND AND AIMS**

According with the Wounds International Consensus of 2012, we know that, in case of infectious wound, we need to use a silver antimicrobial dressing, but it should be better to avoid SilverSulfaDiazine and prefer new medications containing ionic silver. The aim of this work was to investigate, both "in vitro" and "in vivo", if the new SCX technology (SiO<sub>2</sub>-Ag<sup>+</sup>Chlorex) can easily defeat infections and it's really more effective then SSD (SilverSulfaDiazine).

Centro Interdipartimentale per la Cura del  
Piede Diabetico e Centro di Vulnologia



ICCS

# 19<sup>th</sup> International Conference on Wound Management

London (UK) - 25-26 May 2017



## MATERIALS AND METHODS

"In vitro" methods: we tested "in vitro" the effectiveness of both silver materials using a pool of 5 strains: Pseudomonas Aeruginosa, Staphylococcus aureus, Escherichia Coli, Enterococcus hirae and Candida Albicans. 100  $\mu$ l of this pool have been seeded on Petri dishes and kept for 24 hours in incubation at 37 C°.

"In vivo" methods: we enrolled patients with multiple infectious chronic wounds (according with Cutting & Harding criteria for infection); after a qualitative evaluation of the wounds bacterial population, taking a sample by plug, we included in the study 6 patients for a total of 10 wounds, infected by one or more of the microorganisms used for the "in vitro" test. The protocol consisted of a treatment with a spray powder of SSD every 48 hours for 14 days; in case of worsening we should have to start a new treatment with a spray powder containing silicon dioxide, ionic silver and chlorexidn ( $\text{SiO}_2^-$   $\text{Ag}^+$ Chlorex) every 48 hours for 14 days. We evaluated the number of clinical signs of infection and the disappearance or not of the wound edge erythema.



ICCS


# 19<sup>th</sup> International Conference on Wound Management

London (UK) - 25-26 May 2017



## RESULTS

"In vitro" results: SSD demonstrated a wide zone of inhibition within 24 hours, but after 5 days there was no more signs of inhibition; on the contrary SCX had a good inhibition ring that lasted more than 5 days.



**SCX 5 days later**

**SSD 5 days later**

"In vivo" results: all wounds treated with SSD got worse; the signs of infection increased and the wound edge erythema didn't disappear. According with the protocol, we treated then all wounds with SCX and they all improved within the period of observation with complete disappearance of clinical signs of infection and no more wound edge erythema.



# 19<sup>th</sup> International Conference on Wound Management

## London (UK) - 25-26 May 2017



ICCS

Centro Interdipartimentale per la Cura del  
 Piede Diabetico e Centro di Vulnologia

TREATMENTS →	SilverSulfaDiazine Treatment						SiO <sub>2</sub> -Ag <sup>+</sup> Chlorex Treatment					
EVALUATIONS →	Infection Signs*			W. E. Erythema**			Infection Signs*			W. E. Erythema**		
PATIENTS ↓	T0	T7	T14	T0	T7	T14	T0	T7	T14	T0	T7	T14
Pt N°1: wound 1	2	3	3	---	---	X	3	1	---	X	---	---
Pt N°1: wound 2	2	2	3	---	---	X	3	2	1	X	---	---
Pt N°1: wound 3	2	3	4	---	X	X	4	2	---	X	---	---
Pt N°2: wound 4	3	3	5	---	---	X	5	2	---	X	---	---
Pt N°2: wound 5	2	3	4	---	---	X	4	2	---	X	---	---
Pt N°3: wound 6	2	3	3	---	X	X	3	2	---	X	---	---
Pt N°3: wound 7	3	3	4	---	X	X	4	1	1	X	X	---
Pt N°4: wound 8	2	2	3	---	---	X	3	1	---	X	---	---
Pt N°5: wound 9	2	3	5	---	X	X	5	2	---	X	---	---
Pt N°6: wound 10	2	2	4	X	X	X	4	1	1	X	X	---
Global Population	2.2	2.7	3.8	1	5	10	3.8	1.6	0.3	10	2	---
		+22.7%	+72.7%	10%	50%	100%		-57.9%	-92.1%	100%	20%	

\*Number of infection signs according with “Cutting & Harding Criteria”

\*\*Wound edge erythema (more than 1 centimeter)

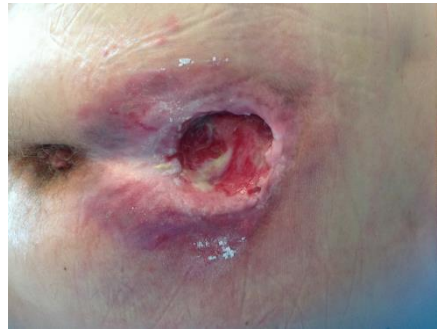All wounds treated with SSD got worse; the signs of infection increased and the wound edge erythema didn't disappear.

All wounds treated with SCX improved within the period of observation with complete disappearance of clinical signs of infection and no wound edge erythema.

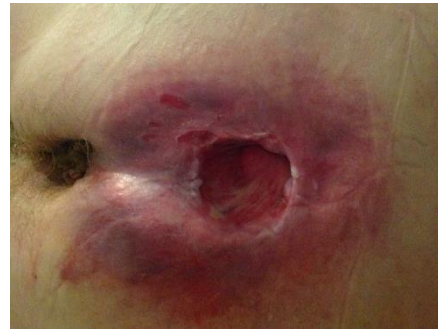

ICCS

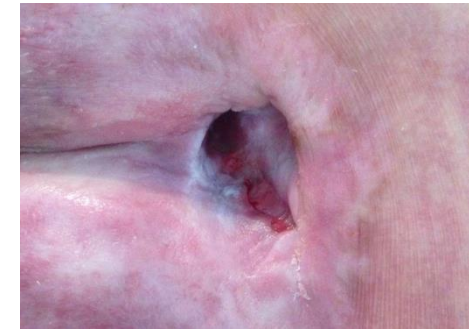# 19<sup>th</sup> International Conference on Wound Management London (UK) - 25-26 May 2017



Beginning of the study



SSD: 14 days later



SCX: 14 days later

## CONCLUSIONS

The study demonstrated the effectiveness of  $\text{SiO}_2\text{-Ag}^+\text{Chlorex}$ , especially in terms of long lasting antimicrobial action. We had the same results "in vitro", so that there has been a perfect correspondence between the laboratory outcomes and the clinical ones.

# Thank You

## Roberto Cassino



"Città Studi" Clinical Institute - Milan (Italy)



Diabetic Foot and Vulnology Treatment & Research Center

Centro Interdipartimentale per la Cura del  
Piede Diabetico e Centro di Vulnologia